

Chapter 6

Joint Vibration Analysis (JVA)

Ray M. Becker, DDS, FAGD

International Certifying and Interpretation Instructor of the Total BioPAK System, Private Practice, USA

ABSTRACT

This chapter describes Joint Vibration Analysis (JVA) technology that assesses pathological changes that can occur within the Temporomandibular joints. Joint Vibration Analysis (JVA) uses tissue accelerometers to objectively capture vibrations given off by structurally compromised internal TM Joint anatomy. The structural breakdown leads to altered mandibular movement patterns during chewing function. Different attributes of representative JVA vibrations have been shown to indicate the presence of various disease states often seen within the Temporomandibular Joint complex. After being recorded, the JVA software displays the various vibration waveforms for clinician analysis to determine the specific internal derangement present. This chapter provides an overview of the various vibratory waveforms that indicate TM Joint pathology and illustrates the utility of Joint Vibration Analysis as a Temporomandibular Joint diagnostic adjunct.

INTRODUCTION

Temporomandibular Joint (TMJ) Anatomy

The Temporomandibular joint (TMJ) is a ginglymoarthroidial joint, which is also diarthroidal, in that it translates and rotates throughout function. It is comprised of the following components:

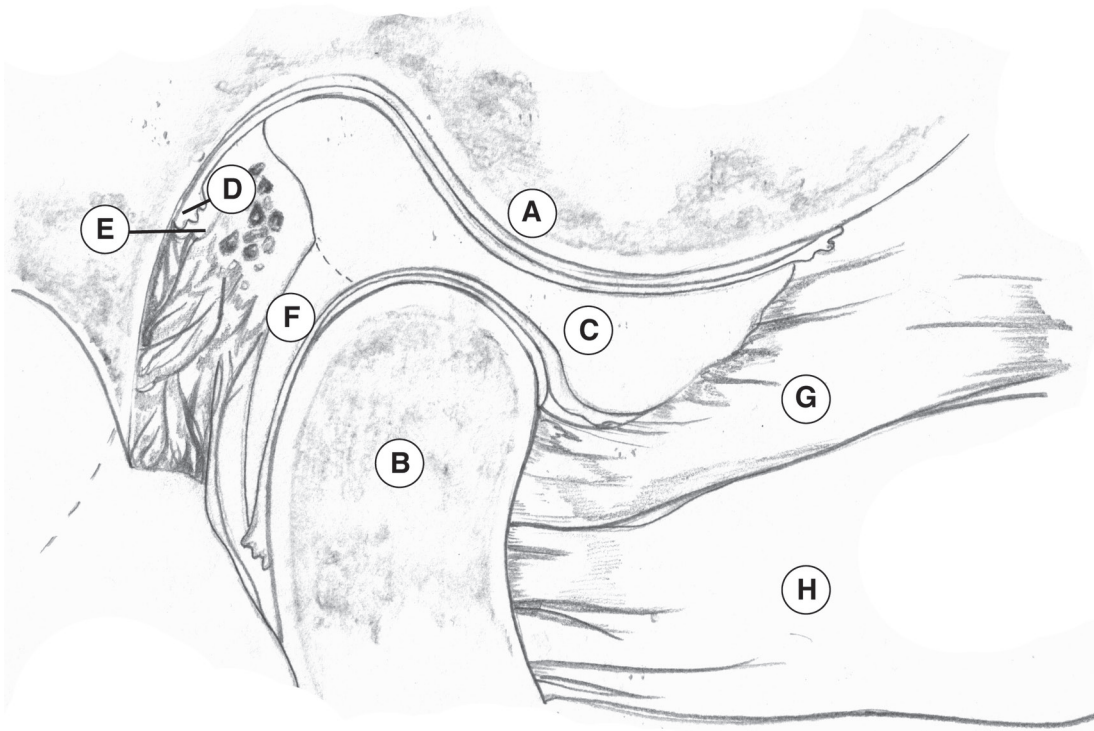
- The posterior slope of the eminentia,
- The mandibular condyle,
- The articular disc
- The synovial tissue

- The vascular and innervated retrodiscal tissue, which includes the posterior attachment of the articular disc to both the mandible and to the temporal bone
- The posterior attachment tissue, which is vascular and innervated

The articular disc is a biconcave fibro-cartilaginous capsule that normally rests between the head of the mandibular condyle and the articular eminence of the temporal bone. The disc is attached to the lateral and medial poles of the condyle, while also being elastically attached posteriorly to the temporal bone and the mandible. Anteriorly, the disc is attached to a

DOI: 10.4018/978-1-4666-6587-3.ch006

Figure 1. Lateral cross-sectional view through the right Temporomandibular joint showing: A-posterior slope of eminentia with typical convex contour; B-mandibular condyle; C- biconcave articular disc fitted between a convex eminentia and a convex condylar head; D-synovial tissue; E-retrodiscal tissue including the posterior attachment of articular disc and temporal bone; F-posterior attachment tissue which is innervated and vascular; G-superior belly of lateral pterygoid muscle with fibers attaching to medial aspect of articular disc; H-inferior belly of lateral pterygoid muscle attaching to condyle. (Adapted by Breanna Becker from, Dawson, P.E. (2008). *Functional Occlusion: From TMJ to Smile Design*, Chapter 5; *The Masticatory Musculature.*, C.V. Mosby, Elsevier. Used with permission.)



few fibers of the superior belly of the lateral pterygoid muscle, which assists in translating both the disc and the condyle forward upon excursions of the mandible (Figure 1).

Through normal excursive movements of the mandible, the Temporomandibular joint is required to both rotate and translate. A healthy joint will perform this task without giving off any sounds or vibrations throughout its entire range of motion (Ishigaki, Bessette, & Maruyama, 1993).

In a healthy occlusion, during function there exists synergy with the coordination of the firing and relaxation of the opposing elevator and depressor muscles (Higashi, 1989). Masticatory muscle coordination results from the sensory input of the teeth, the muscles themselves, the Periodontal Ligaments, the tongue, and the oral soft tissues. The input from these organs creates a pattern of muscle activity, or muscle engrams, that are founded within a pool of neurons located within the brainstem, that is known as the Central Pattern Generator (CPG) (Lund, 1991;

52 more pages are available in the full version of this document, which may be purchased using the "Add to Cart" button on the publisher's webpage:

www.igi-global.com/chapter/joint-vibration-analysis-jva/122074

Related Content

Classification of Lung Images of COVID-19 Patients With the Application of Deep Learning Techniques

C. Meenakshi, S. Meyyappan, A. Ganesh Ram, M. Vijayakarhick, N. Vinothand Bhopendra Singh (2024). *Advancements in Clinical Medicine* (pp. 66-79).

www.irma-international.org/chapter/classification-of-lung-images-of-covid-19-patients-with-the-application-of-deep-learning-techniques/346191

Neuroscience Technology and Interfaces for Speech, Language, and Musical Communication

Dionysios Politis, Miltiadis Tsalighopoulos and Georgios Kyriafinis (2019). *Advanced Methodologies and Technologies in Medicine and Healthcare* (pp. 403-419).

www.irma-international.org/chapter/neuroscience-technology-and-interfaces-for-speech-language-and-musical-communication/213616

Comparative Analysis of 2D USG Technique and Landmark Technique for Right Internal Jugular Vein Cannulation

Vithal K. Dhulkhed, N. V. Kanase, P. B. Jamale and Nagham Mahmood Aljamali (2024). *Advancements in Clinical Medicine* (pp. 80-91).

www.irma-international.org/chapter/comparative-analysis-of-2d-usg-technique-and-landmark-technique-for-right-internal-jugular-vein-cannulation/346192

Analysis of Color Image Encryption Using Multidimensional Bogdanov Map

R. N. Ramakant Parida, Swapnil Singhand Chittaranjan Pradhan (2019). *Histopathological Image Analysis in Medical Decision Making* (pp. 202-225).

www.irma-international.org/chapter/analysis-of-color-image-encryption-using-multidimensional-bogdanov-map/212545

Defining and Characterizing the Landscape of E-Health

Yvonne O'Connor and Ciara Heavin (2019). *Advanced Methodologies and Technologies in Medicine and Healthcare* (pp. 377-390).

www.irma-international.org/chapter/defining-and-characterizing-the-landscape-of-e-health/213614