

Symmetry Detection in Brain Image Analysis

M

Surani Anuradha Jayasuriya

School of Information and Communication Technology, Griffith University, Australia

Alan Wee-Chung Liew

School of Information and Communication Technology, Griffith University, Australia

Phillip Sheridan

School of Information and Communication Technology, Griffith University, Australia

INTRODUCTION

Recent advances in imaging technology have revealed its potential in transforming many aspects of clinical medicine. Modern neuroimaging techniques provide a vast amount of anatomical and functional information of the brain. Computer-aided quantitative neuroimage analysis techniques can be utilized to facilitate the diagnostic capability and patient treatment. However, despite the extensive research, computer-aided brain image analysis has proven to be a difficult problem (Hahn, 2010). Conventional methods are mainly based on the intensity information contained in images. Recently, attention has been turned towards the incorporation of prior knowledge based on anatomical features to improve the accuracy (Clark et al., 1998). One way to integrate such knowledge is to use brain symmetry information.

The brain is highly symmetrical with only small variations. Study of brain symmetry is done by (Hugdahl, 2005; Maes et al., 1999). The highly symmetrical distribution of brain tissues provides an excellent opportunity for symmetry-aided diagnosis. Many researchers have been motivated by this to develop symmetry integrated methods for brain image analysis. In order to retrieve symmetry information from a brain image, it is crucial to identify the precise location of the brain symmetry plane. A number of methods have been proposed for brain symmetry detection.

The aim of this article is to provide an overview of the current state of knowledge of quantitative analysis of symmetry in neuroimages together with brain symmetry plane detection techniques, and challenges.

BACKGROUND

Role of Computer-Aided Image Analysis Techniques in Neurological Practice

Neurological diseases are hard to diagnose due to their complex nature. Studies have reported that severe cortical volume loss (atrophy) is a consistent neuro-pathological finding in many brain disorders (Mouton et al., 1998). Absolute volumes and the spatial distribution of brain atrophy are of major interest when studying the course of neurodegenerative diseases, such as Multiple Sclerosis, Alzheimer's disease (AD), and Schizophrenia.

The imaging modalities most often used for diagnosis of brain diseases are magnetic resonance imaging (MRI) and X-ray computed tomography (CT). While neurological studies have greatly benefitted by high resolution in vivo neuroimaging, assessment of these images are generally performed manually by radiologists. Manual processing of a large number of scans is a time consuming and tedious task. Moreover, the image-derived measurements taken by manual delineation of structures of interest by a radiologist can be affected by inter- and intra-operator variability and poor reproducibility. Various artifacts in different imaging modalities can also compromise accurate image interpretation. It becomes important to develop objective methods for accurate measurement of brain atrophy or localization of pathology.

Computers excel in performing quantitative tasks. In neuroimaging, one of the questions that computers

DOI: 10.4018/978-1-4666-5888-2.ch554

can answer more reliably than humans is in regards to the precise quantification of the degree to which a tissue type has changed (Hahn, 2010). In order to facilitate accurate detection of abnormalities and quantification, intensive research has been conducted on automatic medical image analysis. Advantages of an automated method include objectivity, reproducibility and the capability to process a large number of images (Jayasuriya and Liew, 2012).

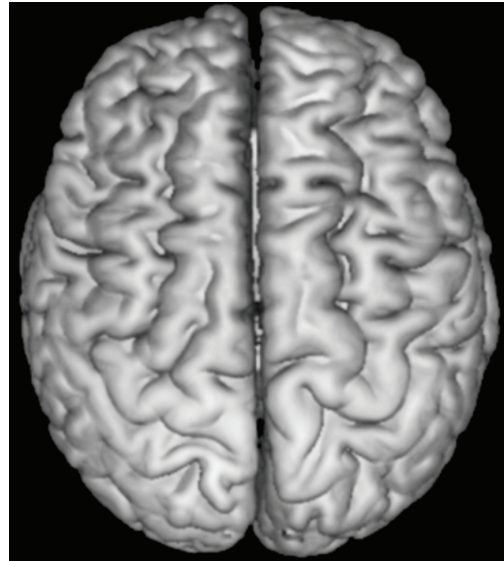
However, despite several decades of research, automatic analysis of brain images still remains a challenging task due to the anatomical complexity of the brain as well as the various noise artifacts in brain images. For example, in magnetic resonance images, artifacts such as intensity non-uniformity (Liew and Yan, 2006) give rise to smooth intensity variation across the image (Figure 1). Recently, attention has turned towards incorporating knowledge gained from brain anatomy and principles used by medical experts. One strategy is to utilize brain symmetry which is routinely employed by expert clinicians in order to identify brain pathologies, such as stroke, tumor and atrophy. This approach compares suspicious tissues to healthy tissues in other regions of the brain.

Brain Symmetry and Its Clinical Implications

The structure of a normal human brain is highly symmetrical, although it also exhibits some degree of asymmetry: The right frontal lobe is larger than the left one, and the left occipital lobe is larger than the right one (Hugdahl, 2005). However, the two hemispheres have approximately identical anatomical properties. The long and deep furrow that separates the two brain hemispheres is known as the inter-hemispheric fissure (IF). Although the real separating surface between the hemispheres is not perfectly planar, the plane that best approximates this surface is considered to be the mid-sagittal plane (MSP), or brain symmetry plane.

Radiologists routinely use symmetry as one of the most discriminating features in conjunction with other characters such as location, neighborhood relationship, and shape, to assess abnormalities in brain images. By looking at a medical image, an expert clinician identifies the symmetry axis/plane and then compares the abnormality with the healthy side of the brain (Liu, 2009). Although the degree of asymmetry has long

Figure 1. An image of a human brain: It is highly symmetrical. The deep groove, known as the inter-hemispheric fissure separates the two hemispheres.



been thought to be helpful for providing a diagnostic cue for clinicians (Khotanlou et al., 2009), automated neuroimage analysis methods to date have not fully exploited knowledge of brain symmetry. The process of extracting symmetry information from brain images can be compromised by the normal variance of anatomical asymmetries.

RESEARCH IN BRAIN SYMMETRY AND ASYMMETRY

Watkins et al. (2001) presented a voxel-based statistical analysis of human brain MR images. Their study included 142 normal brain scans along with their mirror images that were linearly transformed using a symmetrical template. Their results revealed the approximate symmetry in the brain and asymmetry in certain areas.

Symmetry features can be helpful for diagnosis in many cases, such as Alzheimer's Disease (AD), tumor and schizophrenia. For example, asymmetry between left and right hippocampal volumes have been found in patients with schizophrenia (Barrick et al., 2005) and AD (Csernansky et al., 2000). When there is an abnormality, deviation from symmetry can be observed clearly.

7 more pages are available in the full version of this document, which may be purchased using the "Add to Cart" button on the publisher's webpage:

www.igi-global.com/chapter/symmetry-detection-in-brain-image-analysis/113015

Related Content

Development of Communication Skills through Auditory Training Software in Special Education

Eduardo C. Contreras and Isis I. Contreras (2018). *Encyclopedia of Information Science and Technology, Fourth Edition* (pp. 2431-2441).

www.irma-international.org/chapter/development-of-communication-skills-through-auditory-training-software-in-special-education/183956

Hybrid TRS-FA Clustering Approach for Web2.0 Social Tagging System

Hannah Inbarani H and Selva Kumar S (2015). *International Journal of Rough Sets and Data Analysis* (pp. 70-87).

www.irma-international.org/article/hybrid-trs-fa-clustering-approach-for-web20-social-tagging-system/122780

An Efficient Image Retrieval Based on Fusion of Fast Features and Query Image Classification

Vibhav Prakash Singh, Subodh Srivastava and Rajeev Srivastava (2017). *International Journal of Rough Sets and Data Analysis* (pp. 19-37).

www.irma-international.org/article/an-efficient-image-retrieval-based-on-fusion-of-fast-features-and-query-image-classification/169172

Topological Properties of Multigranular Rough sets on Fuzzy Approximation Spaces

B.K. Tripathy, Suwendu Kumar Parida and Sudam Charan Parida (2019). *International Journal of Rough Sets and Data Analysis* (pp. 1-18).

www.irma-international.org/article/topological-properties-of-multigranular-rough-sets-on-fuzzy-approximation-spaces/233594

Comparative Analysis of Applying Behavioral Public Policy to Telecommunication Market by International Organizations

Nagayuki Saito (2021). *Encyclopedia of Information Science and Technology, Fifth Edition* (pp. 1537-1549).

www.irma-international.org/chapter/comparative-analysis-of-applying-behavioral-public-policy-to-telecommunication-market-by-international-organizations/260287